

# Prevention of postsurgical adhesions with N,O-carboxymethyl chitosan: Examination of the most efficacious preparation and the effect of N,O-carboxymethyl chitosan on postsurgical healing

Darren J. Costain, BSc, Renee Kennedy, MD, Curtis Ciona, MD, Vivian C. McAlister, MD,  
and Timothy D. G. Lee, PhD, Halifax, Nova Scotia, Canada

**Background.** Adhesion formation after operation can result in major complications. We have previously demonstrated that N,O-carboxymethyl chitosan (NOCC) is an effective inhibitor of postsurgical peritoneal adhesion formation. However, the optimal form of NOCC (i.e., cross-linked gel versus solution), as well as the best time of administration for optimal reduction in adhesion development, was not investigated. In addition, because adhesion formation and normal wound healing are related events and weakening of wound healing would be a serious drawback to the use of NOCC clinically, we wished to assess the effect of NOCC on the healing of surgical incisions.

**Methods.** Three surgical models were used: (1) an abdominal aortic anastomosis, (2) a large bowel anastomosis, and (3) an abdominal skin incision. In the first model Sprague-Dawley rats received an abdominal aortic transection and repair. NOCC solution or gel was administered at different time points throughout the procedure. Control and NOCC-treated animals were killed 14 days after operation. The condition of the anastomosed vessel was examined, and adhesion frequency and intensity in the abdomen were scored. In the second model Sprague-Dawley rats underwent large bowel transection and repair. Control and NOCC-treated animals were killed on postoperative days 4, 7, and 14, and strength of repair was assessed by removal of the large bowel and measurement of the bursting strength of the repaired incision. In the third model rats received an abdominal incision and were immediately closed. Control and NOCC-treated animals were killed 14 days after operation, and the skin tensile strength of the wound was measured with a tensiometer.

**Results.** In all three models studied, NOCC treatment did not adversely affect the strength of the repaired incision. NOCC solution administered before operation did not greatly reduce adhesion formation, whereas the delivery of both NOCC gel and solution after operation was most efficacious.

**Conclusions.** The administration of both NOCC gel and solution after operation is most efficacious, and NOCC does not compromise postsurgical healing in rats at doses that prevent peritoneal adhesion formation. (Surgery 1997;121:314-9.)

THE FORMATION OF fibrous adhesions after abdominal operation is common and can result in significant morbidity for the patient. For example, adhesions are a major cause of intestinal obstruction and can lead to fistula formation, postsurgical reproductive organ complications, ureteral obstruction, and chronic abdominal-pelvic pain. Furthermore, pericardial adhesions after cardiac operation can result in complications during reoperative cardiac procedures.

We have previously shown that N,O-carboxymethyl chitosan (NOCC), a highly charged long chain polysaccharide with structural similarities to hyaluronic acid,<sup>1</sup> significantly reduces the incidence and severity of postoperative adhesion formation.<sup>2</sup> These studies were performed with a combination of NOCC gel and NOCC solution delivered after operation. Because it is possible that NOCC may influence the early events during operation (such as initiation of extracellular matrix metabolism and dehydration of tissues), we believed it was beneficial to test the addition of solution both before and after operation. The method of delivery of NOCC could also be simplified if only gel or only solution was sufficient to reduce adhesion formation. We therefore tested a panel of methods of NOCC administration to ascertain the most efficacious antiadhesion therapy. In

Supported by Chitogenics Inc., Dartmouth, N. S., Canada.

Accepted for publication August 8, 1996.

Reprint requests: Timothy Lee, PhD, Department of Surgery, Faculty of Medicine, Dalhousie University, Halifax, N.S., Canada B3H 4H7.

Copyright © 1997 by Mosby-Year Book, Inc.

0039-6060/97/\$5.00 + 0 11/56/77190



addition, because many of the cells and events involved in adhesion formation are also involved in the normal healing process,<sup>3-4</sup> it is important to ascertain whether NOCC treatment interferes with wound repair. Poor wound healing in intestinal surgery presents a considerable risk of peritonitis. Retarded incisional repair can lead to wound sepsis, dehiscence, mechanical problems such as wound disruption and hernia formation, and poor cosmetic healing. Moreover, other antiadhesive agents have raised concern over poor wound healing<sup>5</sup> and excessive postoperative bleeding and swelling.<sup>6</sup> Therefore, before clinical trials can be warranted, it must be confirmed that the use of NOCC to reduce adhesion formation does not adversely affect the normal healing process necessary for healthy recovery after operation.

Three rat models were developed to study the effect of NOCC on the healing process after operation: (1) an aortic anastomosis model, (2) a large bowel anastomosis healing model, and (3) an abdominal skin healing model. All three models examined the quality of wound repair in control animals and in animals in which NOCC was applied to the site of the incision. Our data indicate that NOCC, applied to the wound site, does not compromise normal wound healing after operation and that NOCC solution applied before operation is not as effective as postoperative application.

## MATERIAL AND METHODS

NOCC is a derivative of chitosan, which is a long chain polysaccharide. The addition of carboxymethyl groups to chitosan's nitrogen and oxygen centers produces a water soluble, negatively charged, biocompatible polymer (MW, greater than 2 Md) that is hydrophilic, lubricious, and viscoelastic. NOCC is nontoxic, either in vitro in fibroblast culture assays or in vivo in experimentation with intraperitoneal, oral, or subcutaneous treatment at concentrations higher than described in this experimentation. NOCC was administered as a sterile 2% solution initially spread evenly over the peritoneal contents in the area of the incision and then over the entire peritoneal area before closure. NOCC was also administered as a sterile, cross-linked gel directly to the site of the incision.

### Models

**Aortic anastomosis healing.** Adult male Sprague-Dawley rats (Harlan Sprague-Dawley) weighing 250 to 300 gm were anesthetized with an intraperitoneal injection of sodium pentobarbital (60 mg/kg). A midline incision was made in the abdomen, and the animal was exposed with a stainless steel retractor. Under an operating microscope the animal was eviscerated to the left, and the abdominal contents were covered with saline-soaked gauze for the duration of the operation. The inferior vena cava and aorta were exposed proximal to the lum-

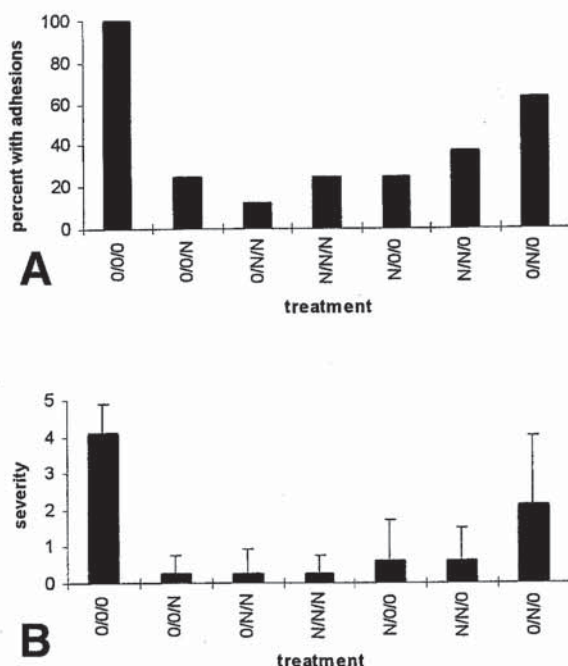
bar outflow, and the vessels were carefully teased apart. Microvascular clamps were used to pinch the aorta proximal and distal to the future site of transection. The aorta was severed with microsurgical scissors, and the free ends were flushed immediately with heparinized saline. Sutures (10.0) were placed at the 9 o'clock and 3 o'clock positions, and end-to-end anastomosis was accomplished with running sutures first on the back, and then the front wall of the vessel. The microvascular clamps were removed, and pressure was maintained on the vessel until bleeding subsided (approximately 1 minute). The viscera were replaced, and the retractor was removed. The muscle and skin were closed separately with running sutures (4.0 Dexon and 3.0 Dermalon, respectively). Animals were permitted to feed ad libitum immediately after operation.

Seven groups of eight animals were used in the study. One group served as the untreated control. In the treated groups NOCC was applied at three time points throughout the operation: 3 ml 2% NOCC solution spread evenly throughout the abdomen before transection, 1 ml NOCC gel applied to repaired aorta after successful anastomosis, and 3 ml 2% NOCC solution spread throughout the peritoneum before closure. The groups are described as follows: (1) 0/0/0, no NOCC treatment (control); (2) N/0/0, 3 ml NOCC solution before transection; (3) 0/N/0, 1 ml NOCC gel after anastomosis, (4) 0/0/N, 3 ml NOCC solution before closure; (5) N/N/0, 3 ml NOCC solution before transection and 1 ml NOCC gel after repair; (6) 0/N/N, 1 ml NOCC gel and 3 ml NOCC solution after repair; and (7) N/N/N, 3 ml NOCC solution before transection and 1 ml NOCC gel and 3 ml NOCC solution after repair.

Animals were killed by cervical dislocation 14 days after operation. The repaired aorta was examined for degradation of suture site and presence of aneurysm-pseudoaneurysm. Two sites were examined for the presence of adhesions. Generalized postoperative abdominal adhesions were assessed by examining adhesions involving the liver. Specific adhesions were assessed by examining the retroperitoneum at the site of the aortic anastomosis. Adhesion intensity was scored on a scale of 0 to 5 as previously described.<sup>2</sup>

**Large bowel anastomosis healing.** Adult male Sprague-Dawley rats weighing 200 to 250 gm were anesthetized with an intraperitoneal injection of sodium pentobarbital (60 mg/kg). A midline incision was made in the abdomen, and the contents were exposed by using a stainless steel retractor. Under an operating microscope the animal was eviscerated to the left, and the viscera were covered with saline-soaked gauze. The descending colon was located, and, after milking any material in the colon downward, a site approximately halfway down the colon was chosen for transection. The transected colon was anastomosed by using six single sutures (6.0 Max-



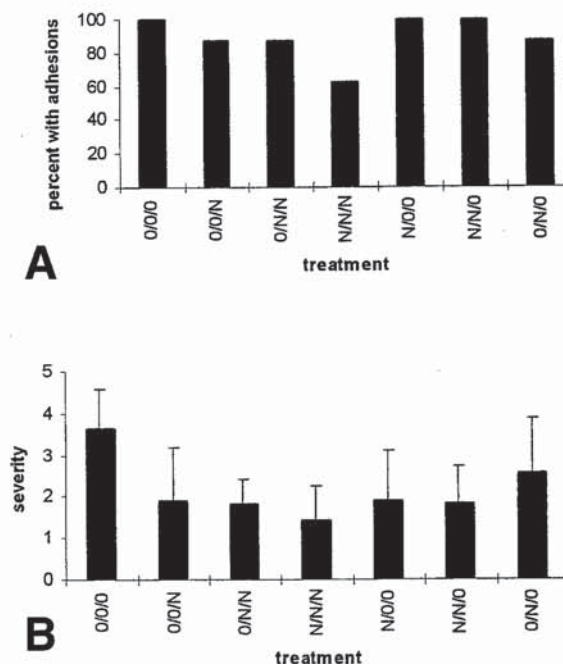


**Fig. 1.** Effect of NOCC on frequency (A) and severity (B) of liver adhesions in aortic anastomosis model. O/O/O, No treatment (control); O/O/N, 3 ml NOCC solution after repair; O/N/N, 1 ml NOCC gel and 3 ml NOCC solution after repair; N/N/N, 3 ml NOCC solution before transection, 1 ml NOCC gel and 3 ml NOCC solution after repair; N/O/O, 3 ml NOCC solution before transection; N/N/O, 3 ml NOCC solution before transection, 1 ml NOCC gel after repair; and O/N/O, 1 ml NOCC gel after repair.

on). After replacement of the viscera, the muscle and skin were closed separately with running sutures (3.0 Dexon). Animals were allowed to feed ad libitum immediately after operation.

Rats were randomly separated into two groups of 18 animals. Control rats received no NOCC treatment. NOCC-treated animals received 3 ml 2% NOCC solution spread evenly over the viscera immediately after opening the abdomen, 1 ml NOCC gel applied directly to the site of transection after repair, and an additional 3 ml NOCC solution spread over the viscera before closure.

Six animals from each group were killed on each of postoperative days 4, 7, and 14. After en bloc removal of the colon, adherent tissue was carefully removed, and a 5 cm section including the anastomosis was obtained. Intestinal sutures remained in place to best approximate the normal clinical situation. One end of the colon section was ligated with suture material, and the remaining end was intubated with a small catheter held in place by ligatures. The catheter was connected to an infuser with an attached manometer. The specimen was



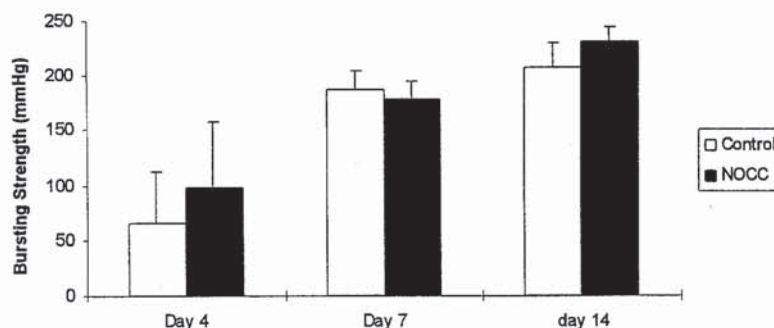
**Fig. 2.** Effect of NOCC on frequency (A) and severity (B) of retroperitoneal adhesions in aortic anastomosis model. See descriptions of treatment groups in Fig. 1.

placed underwater, and air was infused into the section until bubbles could be detected in the water. The pressure required to produce this perforation was recorded as bursting strength in millimeters of mercury.

**Abdominal skin healing.** Adult male Sprague-Dawley rats weighing 250 to 300 gm were anesthetized with an intraperitoneal injection of sodium pentobarbital (60 mg/kg). The abdomen was shaved with standard animal clippers, and the skin was swabbed with 70% ethanol. A longitudinal abdominal incision approximately 6 cm in length was made, and a plane was developed between the skin and the underlying muscle. The muscle was then opened to a similar length. Abdominal muscle and skin were closed separately with running sutures (3.0 Dexon).

Rats were randomly separated into two groups. Ten animals received no NOCC treatment, serving as the control group. The remaining 10 animals received 3 ml 2% NOCC solution immediately after opening. The solution was spread evenly throughout the peritoneal cavity and the area of the skin incision.

Fourteen days after operation animals were killed by cervical dislocation. Any remaining sutures were removed, and a portion of the skin including exactly 2 cm in length of the incision was removed and attached to a tensiometer. Upward pressure was applied directly along the incision, and breaking strength of the incision



**Fig. 3.** Effect of NOCC on bursting strength of large bowel anastomosis repair model. One group received 3 ml NOCC solution before large bowel laceration and 1 ml NOCC gel plus 3 ml NOCC solution after repair. Second group served as untreated control.

was recorded. A small piece of the incision just superior to the sample used to assess rupture strength was processed for routine histologic examination with hematoxylin-eosin and trichrome stains.

**Statistics.** Because the data obtained followed a normal distribution, data were analyzed by using the Student *t* test. Results were considered nonsignificant when *p* values were greater than 0.05.

## RESULTS

**Aortic anastomosis.** The first series of experiments examined the effects of NOCC given either before or after the operation, both in addition to or in the absence of the cross-linked NOCC gel. These experiments used the aortic surgery model. There were two types of adhesions examined: (1) those that were generally distributed and resulted from the abdominal operation and (2) those that were at the site of the aortic repair (i.e., retroperitoneal adhesions). The results of these experiments are shown in Figs. 1 and 2. We used adhesions involving the liver as an adhesion characteristic of abdominal surgery. These adhesions generally involved one or more liver lobes and the site of the incision in the abdominal wall. We found that all treatments that used the NOCC solution distributed evenly throughout the viscera significantly reduced the incidence (Fig. 1, A) and severity (Fig. 1, B) of adhesions of this sort. The best results were found when the NOCC solution was applied after the operation (i.e., before closure). We found no significant benefit of administering NOCC solution before and after operation (group N/N/N) when compared with administering it only after operation (group 0/N/N).

The frequency of adhesions at the site of the aortic anastomosis (retroperitoneal adhesions) was reduced only in those groups that received NOCC solution after operation. Administration of NOCC solution before operation but not after (group N/N/0 in Fig. 2, A) re-

sulted in adhesions in 100% of the animals tested, although the severity of the adhesions was less than control (Fig. 2, B). Both the frequency and the severity of retroperitoneal adhesions were most reduced by the use of the NOCC gel and the solution before and after aortic operation (group N/N/N), but the severity of the adhesions in this group was not significantly different than the group receiving NOCC solution only after operation (group 0/N/N, *p* = 0.59).

In addition to assessing adhesions, we examined the suture site of the aortic repair for evidence of pseudoaneurysms resulting from a weakening of the vessel as a result of NOCC treatment. No evidence of pseudoaneurysm formation could be seen, suggesting that the NOCC had no deleterious effect on the healing of the aortic repair.

**Large bowel anastomosis healing.** The bursting strength of NOCC-treated and untreated anastomosed intestinal segments is presented in Fig. 3. On postoperative day 4 there was considerable variation in the pressure required to rupture the intestinal segments. Nonetheless, no significant difference was noted between the bursting strength of NOCC-treated versus untreated animals at postoperative day 4 (*p* = 0.41). There is less variation in bursting strengths at both postoperative days 7 and 14. Consistent with the results above, no significant difference was noted between the pressures required to rupture the wound in NOCC-treated and untreated animals (*p* = 0.46 and 0.07 for postoperative days 7 and 14, respectively).

**Abdominal skin wound healing.** The tension required to rupture repaired incisional skin wounds is presented in Fig. 4. Although there was considerable animal to animal variation, no significant difference was noted between NOCC-treated and untreated animals at 14 days after operation with respect to wound strength (*p* = 0.87). When slides of the incision site were examined blindly by a registered pathologist (Dr. J. Wright,



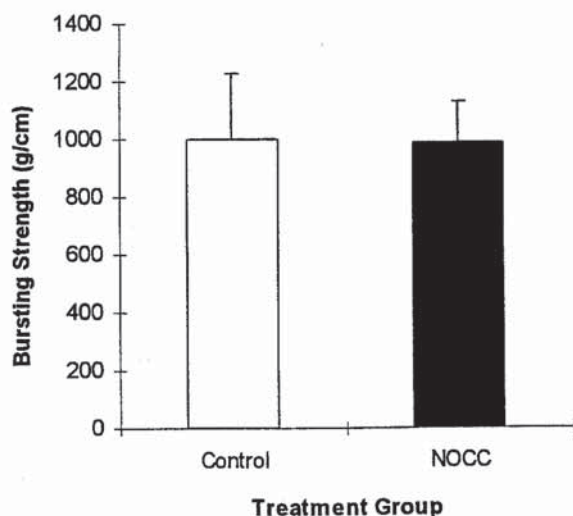


Fig. 4. Effect of NOCC on healing strength of postsurgical abdominal incision. One group received 3 ml NOCC solution before closure, and other group served as untreated control.

I.W.K./Grace Hospital, Halifax, N.S.), no differences could be identified (for example, in collagen deposition) that could discriminate between the experimental (NOCC-treated) and the control groups.

## DISCUSSION

We have previously demonstrated that NOCC decreases both the incidence and intensity of abdominal adhesions in two surgical models.<sup>2</sup> The first was a gynecologic model that entailed damage to the uterine horn of female rats. The second was an intestinal incision model that involved repair of an ileal transection. In both of these models the application of 1% cross-linked NOCC gel and 2% NOCC solution after operation reduced adhesion formation. The cascade of events that results in adhesion formation is characterized by the recruitment of neutrophils, macrophages, and subsequently fibroblasts<sup>7-8</sup> and the local production of various cytokines and growth factors.<sup>9-12</sup> The initiation of these events is complex and involves factors released at the time of trauma, particularly extracellular matrix proteins from the wound site. Moreover, the clotting pathway results in immediate events that facilitate the initiation of adhesion formation. For these reasons it seemed reasonable to assume that coating the viscera with a NOCC solution before surgical manipulation could be of significant importance with respect to inhibiting postsurgical adhesion formation. On the other hand, because NOCC is lubricious, pretreatment could lead to difficulties in fine surgical procedures. It was therefore important to examine when NOCC solution and gel should be applied to maximize the benefit and minimize adverse effects on surgical procedure.

The results with the aortic sectioning model clearly demonstrated that the best antiadhesion effects are obtained when NOCC gel is applied directly after operation in combination with NOCC solution applied before closure (Figs. 1 and 2). There was no significant benefit in adding NOCC solution before surgical manipulation. The effects of the NOCC solution were most obvious in the adhesions associated with abdominal operation. The liver was used as an example because it is often involved in peritoneal adhesions in rats. The use of NOCC solution before closure had a dramatic effect on both the incidence and severity of adhesions involving the liver in this model. At the site of the anastomosis the effect of the combination of both gel and solution was better than gel alone but not as pronounced as the difference seen in the case of the adhesions occurring in response to the abdominal trauma in general. These data suggest that the application of NOCC gel at the site of anastomosis, followed by NOCC solution spread throughout the viscera, is the most efficacious manner to use NOCC preparations to inhibit peritoneal adhesion formation.

Because the events that precede adhesion formation are common to both adhesion development and wound healing,<sup>3,4</sup> it was necessary to confirm that NOCC does not adversely affect normal wound healing and healthy recovery after operation. Other antiadhesion agents have been found to have such limitations.<sup>13-18</sup> We demonstrated here that the application of NOCC gel and solution does not decrease the strength of a large bowel anastomosis when compared with control animals. No significant difference was noted in the strength of the repaired incision at postoperative days 4, 7, and 14. This indicates that NOCC, applied at doses shown to decrease the incidence and severity of peritoneal adhesions,<sup>2</sup> will not result in increased risk of perforation after intestinal operation. This corroborates the experimentation above examining the healing of high pressure aortic anastomosis in the rat. The fact that no aneurysms or pseudoaneurysms were seen at the repair site of this high pressure model confirms that the aortic healing was not compromised by treatment with NOCC. Likewise, the healing of the abdominal skin incision appeared normal both morphologically and as assessed by strength of the healed wound.

The mechanism of action by which NOCC reduces the incidence and severity of adhesions after abdominal operation is unclear. Many of the inflammatory events that initiate adhesion formation are also involved in the wound healing process. The fact that NOCC is able to prevent adhesion formation while not affecting the wound healing response suggests that there are fundamental differences in the early events that lead to these two related processes. NOCC may provide a tool to explore these differences in future experimentation and may be of significant clinical benefit.



# REFERENCES

1. Davies DH, Elson CM, Hayes ER. N,O-carboxymethylchitosan, a new water soluble chitin derivative. In: Sljāk-Bræk G, Anthonsen T, Sanford P, editors. Chitin and chitosan. London: Elsevier Applied Science, 1989:467-72.
2. Kennedy R, Costain DJ, McAlister V, Lee TDG. Prevention of experimental postoperative peritoneal adhesions by N,O-carboxymethyl chitosan. *Surgery* 1996;120:866-70.
3. Riches DWH. The multiple roles of macrophages in wound healing. In: Clark RAF, Henson PM, editors. The molecular and cellular biology of wound repair. New York: Plenum Press, 1988: 213-39.
4. Rodgers KE, diZerega GS. Function of peritoneal exudate cells after abdominal surgery. *J Invest Surg* 1993;6:9-23.
5. Vander Salm TJ, Okike ON, Marsicano TH, Compton C, Espinoza E. Prevention of postoperative pericardial adhesions. *Arch Surg* 1986;121:462-7.
6. Wiseman DM, Kamp L, Linsky CB, Jochen RF, Pang RHL, Scholz PM. Fibrinolytic drugs prevent pericardial adhesions in the rabbit. *J Surg Res* 1992;53:362-8.
7. Milligan DW, Raftery AT. Observations on the pathogenesis of peritoneal adhesions: a light and electron microscopical study. *Br J Surg* 1974;61:274-80.
8. Ryan GB, Brobety J, Najno G. Mesothelial injury and recovery. *Am J Pathol* 1973;71:93-112.
9. Hershlag A, Otterness IG, Bliven ML, Diamond MP, Polan ML. The effect of interleukin-1 on adhesion formation in the rat. *Am J Obstet Gynecol* 1991;165:771-4.
10. McBride WH, Mason K, Withers HR, Davies C. Effect of interleukin 1, inflammation, and surgery on the incidence of adhesion formation and death after abdominal irradiation in mice. *Cancer Res* 1989;49:169-73.
11. Kovacs EJ, Brock B, Silber IE, Neuman JE. Production of fibrinogenic cytokines by interleukin-2-treated peripheral blood leukocytes: expression of transforming growth factor- $\beta$  and platelet derived growth factor B chain genes. *Obstet Gynecol* 1993;82:29-36.
12. Kovacs EJ. Fibrogenic cytokines: the role of immune mediators in the development of scar tissue. *Immunol Today* 1991;12:17-23.
13. Evans DM, McAree K, Guyton DP, Hawkins N, Stakleff K. Dose dependency and wound healing aspects of the use of tissue plasminogen activator in the prevention of intra-abdominal adhesions. *Am J Surg* 1993;165:229-32.
14. Holmdahl LE, Al-Jabreen M, Risberg B. Role of fibrinolysis in the formation of postoperative adhesions. *Wound Rep Reg* 1994; 2:171-6.
15. Guyton DP, Guy J, Sloan K, Evans DM. Decreased fascial wound strength following intraperitoneal injection of tissue plasminogen activator. *Surg Forum* 1989;40:34-5.
16. Connolly JE, Smith JW. The prevention and treatment of intestinal adhesions. *Surg Gynecol Obstet* 1960;110:417-31.
17. Ellis H. The cause and prevention of postoperative intraperitoneal adhesions. *Surg Gynecol Obstet* 1961;113:547-50.
18. Jansen RPS. Tubal resection and anastomosis. I. Sterilization-reversal. *Aust N Z J Obstet Gynaecol* 1986;26:294-9.

## BOUND VOLUMES AVAILABLE TO SUBSCRIBERS

Bound volumes of *Surgery* are available to subscribers (only) for the 1997 issues from the publisher at a cost of \$81.50 for domestic, \$108.61 for Canadian, and \$101.50 for international subscribers for Vol. 121 (January to June) and Vol. 122 (July to December). Shipping charges are included. Each bound volume contains a subject index and an author index, and all advertising is removed. Copies are shipped within 60 days after publication of the last issue in the volume. The binding is durable buckram with the JOURNAL name, volume number, and year stamped in gold on the spine. Subscriptions must be in force to qualify. Bound volumes are not available in place of a regular journal subscription. *Payment must accompany all orders.* Contact Mosby-Year Book, Inc., Subscription Services, 11830 Westline Industrial Dr., St. Louis, MO 63146-3318; phone (800)325-4177, ext. 4351, or (314)453-4351.